

# Automated Analysis of Cell Proliferation in Images of BrdU Stained Rat Cecum and Colon

E. Persohn<sup>1</sup>, J. Schreiber<sup>2</sup>, J. Zimmermann<sup>3</sup>

<sup>1</sup> Head of Cellular Imaging, Safety Profiling and Assessment, Pathology, Novartis Pharma AG, Basel, Switzerland

<sup>2</sup> Head of Life Projects, Definiens AG, Munich, Germany

<sup>3</sup> Consultant, Advanced Technology Group, Definiens AG, Munich, Germany

**In the present study, a fully automated system for the measurement of cell proliferation on virtual slides was established and validated. Scanned BrdU stained sections of rat cecum and colon were analyzed using the Definiens Enterprise Image Intelligence™ Suite. For validation of the system, results from Definiens analysis were compared to counts performed by four different scientists on the same randomly selected image tiles and proved to be within the range of the results from manual counting. With this scanning and image analysis technique, a larger area of tissue can be evaluated in a shorter timeframe, resulting in more robust results without painful and time consuming manual work.**

## 1. Background

Cell proliferation studies have been an indispensable tool for assessing the carcinogenic potential of drug candidates for many years. Recently, scanning systems have become available which facilitate scanning of whole slides with several organ sections. Up to now, analysis of these virtual slides was restricted to either manual counting or semi-automated systems that required tedious hands-on steps, thus absorbing valuable resources for routine work.

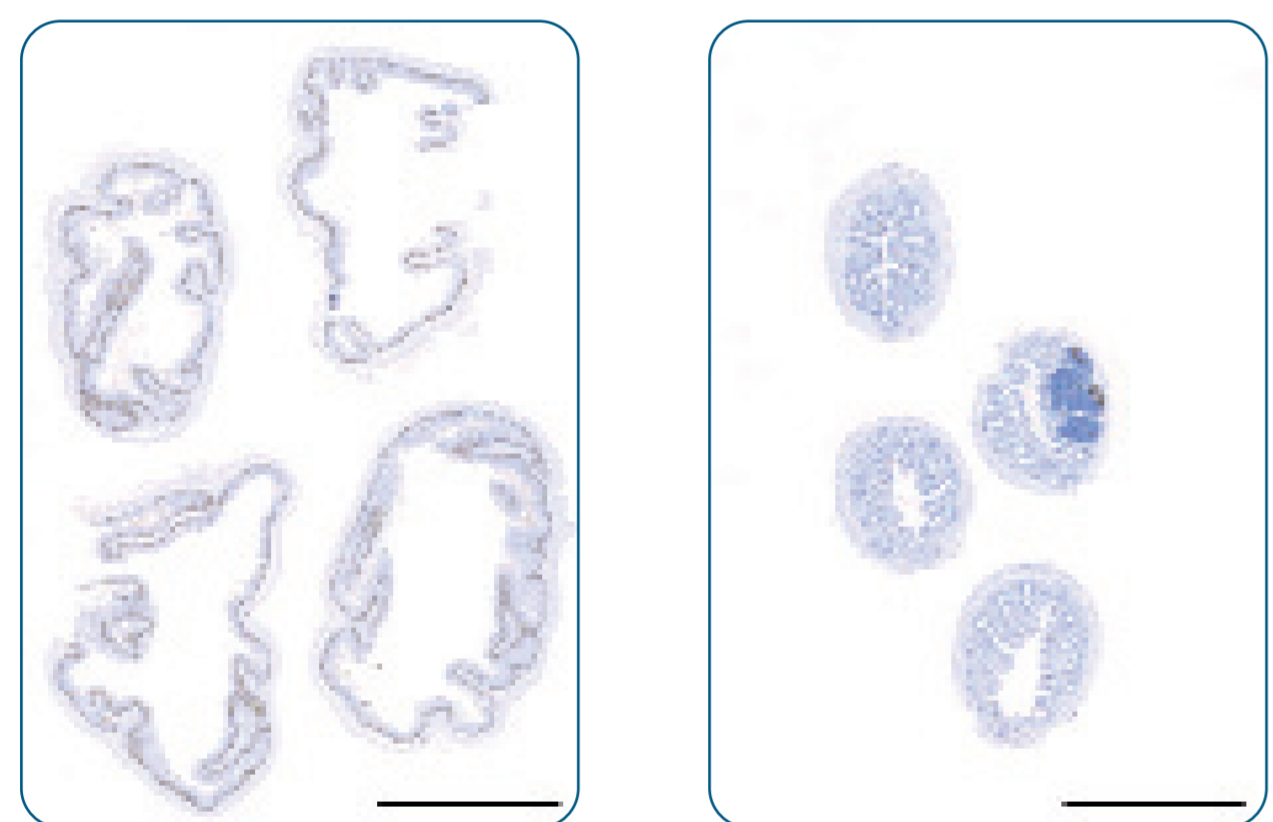
By contrast, fully automated image analysis - integrated into an environment of automated staining and automated image acquisition – would overcome the last bottleneck in high throughput toxicological studies.

## 2. Aim

The aim of the present study was to evaluate the performance and precision of a new generation of image analysis software, Definiens Enterprise Image Intelligence (EII), for fully automated detection of regions of interest and determination of BrdU labeling indices on virtual slides in comparison with the results from manual counting.

## 3. Materials and Methods

Of 10 treated and 10 untreated rats, 4 histological sections of cecum and colon, respectively, were used for BrdU immunostaining. Subsequently, all 8 sections per animal were scanned using the MIRAX Scan System (Carl Zeiss AG, Germany).



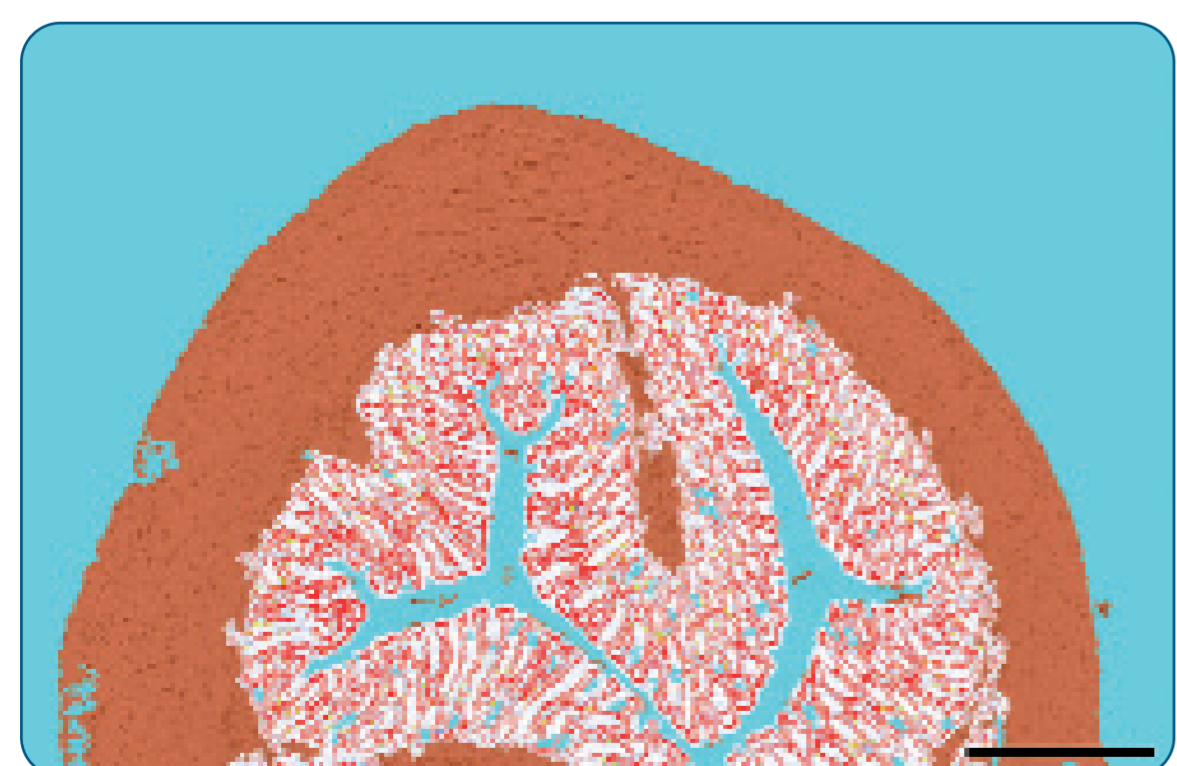
**Fig. 1** Virtual slides of cecum (a) and colon (b), acquired using the Zeiss Mirax Scan system (entire slides). Bar 5 mm.

Following image acquisition, virtual slides were analyzed using the Definiens Enterprise Image Intelligence Suite. Two rule sets for cecum and colon, respectively, written in Definiens Cognition Network Language (CNL), were developed specifically for this application, covering analysis steps on all scales, ranging from automatic detection and quantification of the mucosal area within both organs to detailed classification and counting of positive and negative nuclei for determination of the BrdU labeling index (LI) on automatically generated image tiles.

Results from the analysis using Definiens software were validated by manual counting on randomly selected tiles.

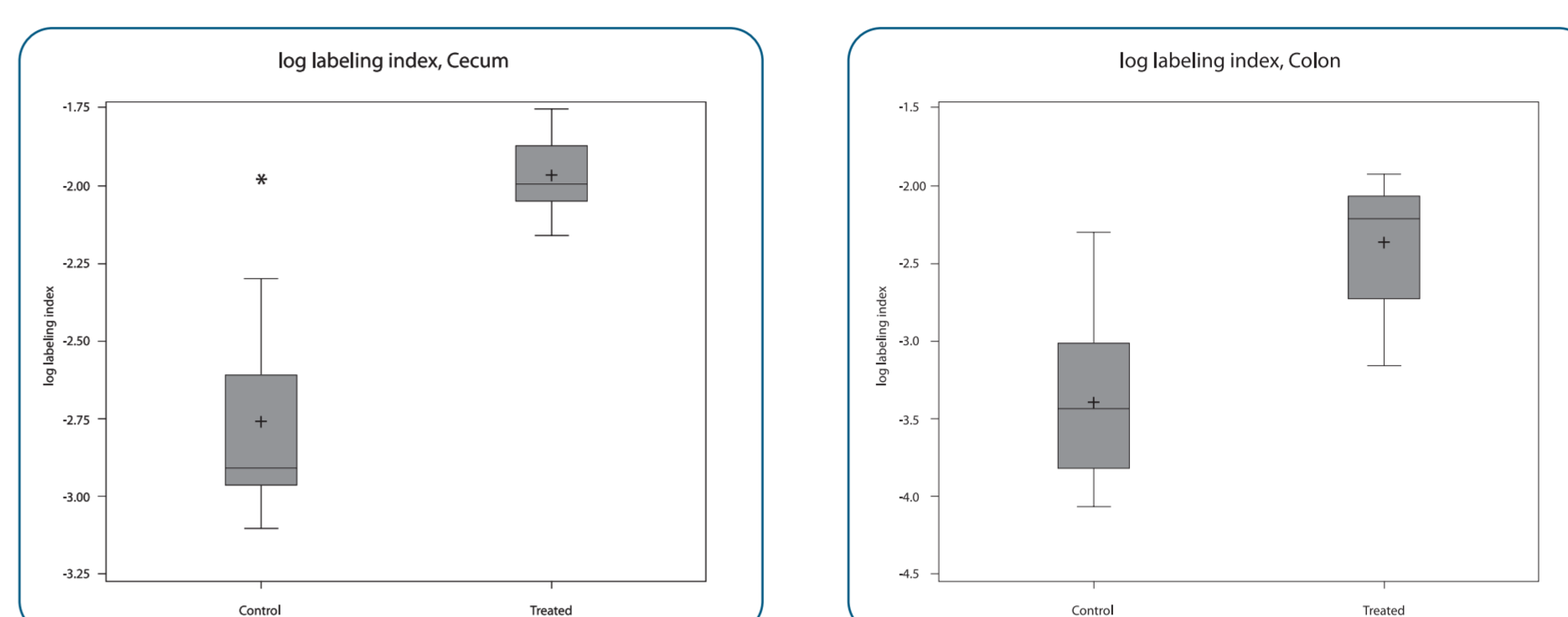
## 4. Results

Since microscopic analyses of cecum and colon sections immunostained with anti-BrdU antibody revealed that cell proliferation was mainly confined to the mucosa, detection of this area constituted the first step in the rule sets for automated colon and cecum analysis (Fig. 2).



**Fig. 2** Definiens result: Detection of the colon mucosa. Regions excluded from analysis (e.g. muscularis) are shown in brown. Bar 200 µm.

Determination of BrdU positive and negative nucleus numbers as well as determination of labeling indices (Fig. 3) was reliably restricted to mucosal areas. Additionally, a comparison of two datasets was performed: From one dataset images in which automatic mucosa detection exhibited deficiencies were removed; the other dataset had undergone no visual check and comprised all images. LI calculations were very similar for both datasets. Hence, no further manual correction step is needed in the workflow and the system is fully automatable.

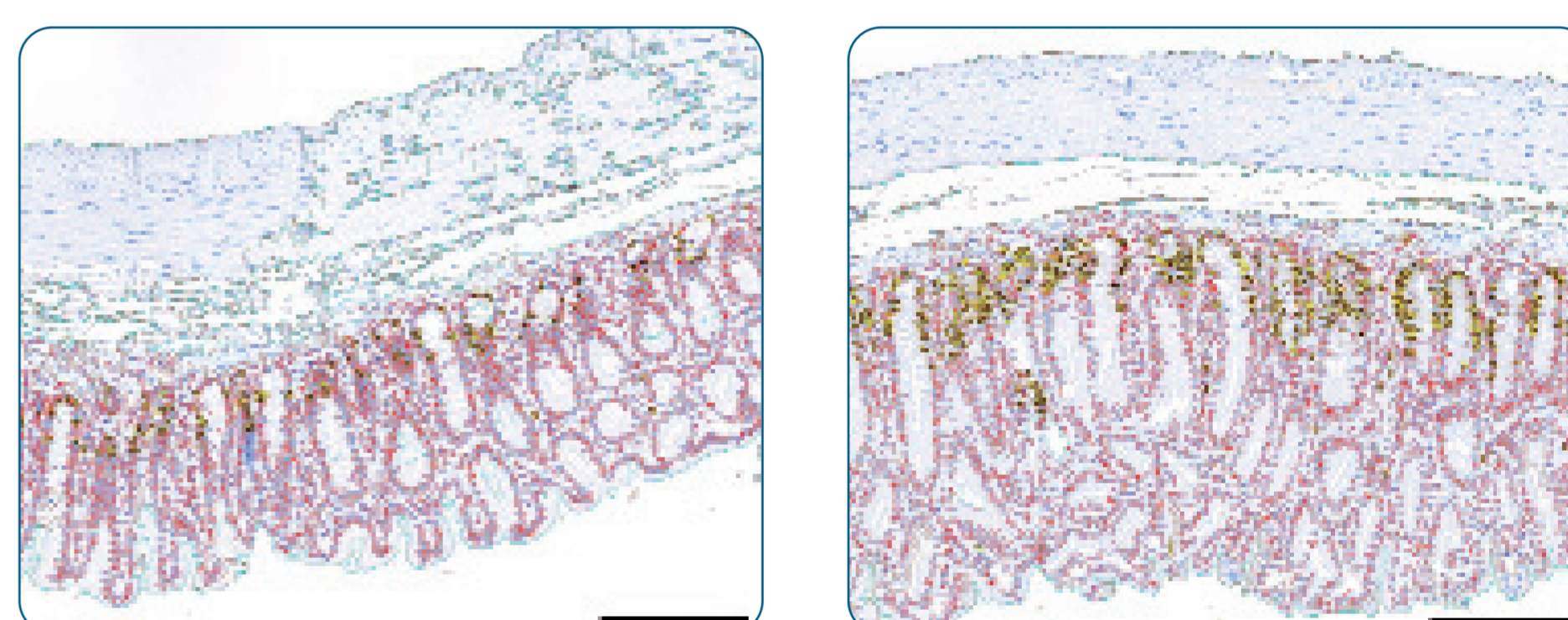


**Fig. 3** Boxplots for log labeling index per group, cecum (left) and colon (right)

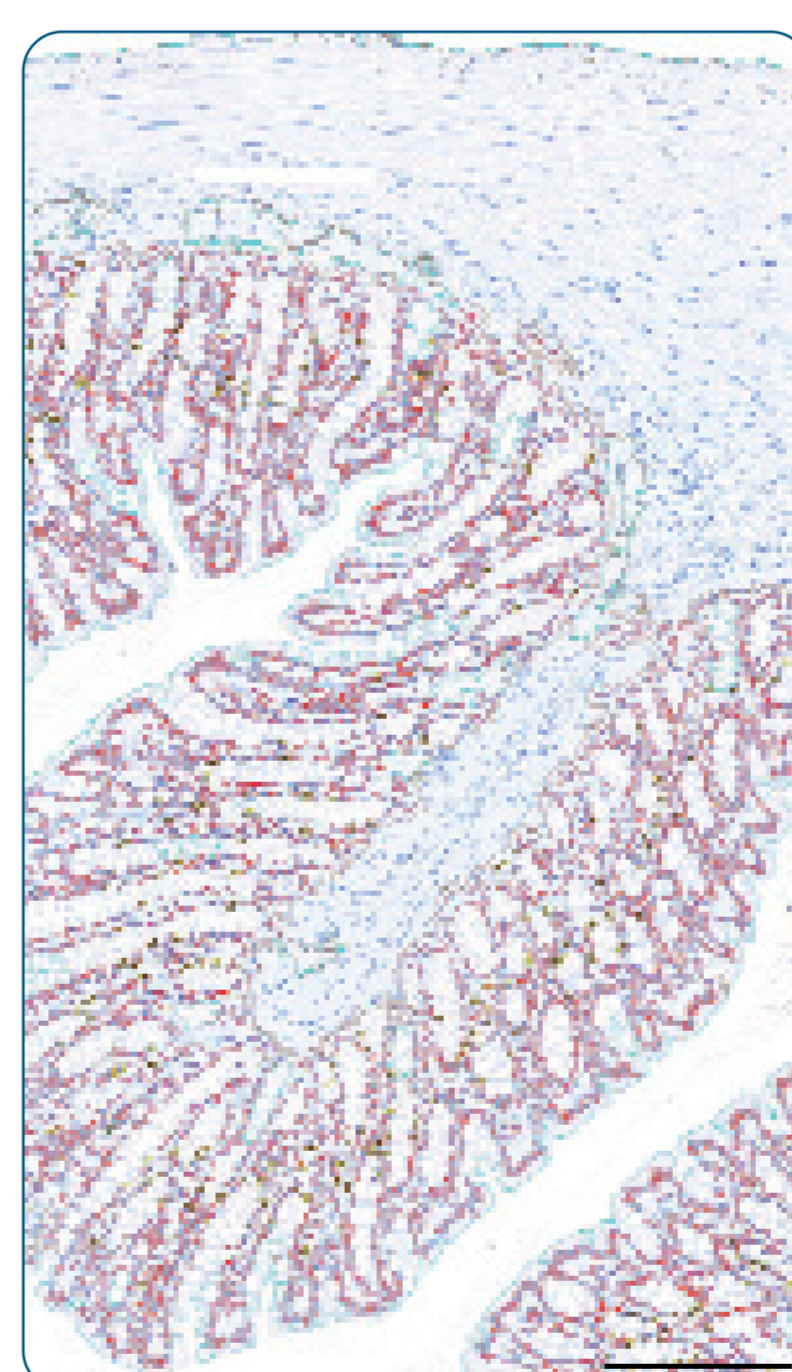
The sum as well as single tile data and resulting labeling index (LI) from automatic (Definiens) counting results for negative (Neg) and positive nuclei (Pos) of cecum and colon were within the manual counting results  $\pm 10\%$  (Table 1).

	Cecum				Colon			
	Total nuclei (sum)	Neg (mean)	Pos (mean)	LI	Total nuclei (sum)	Neg (mean)	Pos (mean)	LI
Manual 1	19015	1633.3	95.4	5.51	7344	1433.0	35.8	2.44
Manual 2	19846	1710.8	93.4	5.17	6545	1275.2	33.8	2.58
Manual 3	20164	1748.1	85.0	4.64	8250	1600.6	49.4	2.99
Manual 4	19249	1663.8	86.1	4.91	7209	1403.8	38.0	2.64
Manual 5	18886	1627.1	89.8	5.42				
Definiens	19427	1670.1	96.0	5.44	7537	1473.8	33.6	2.23

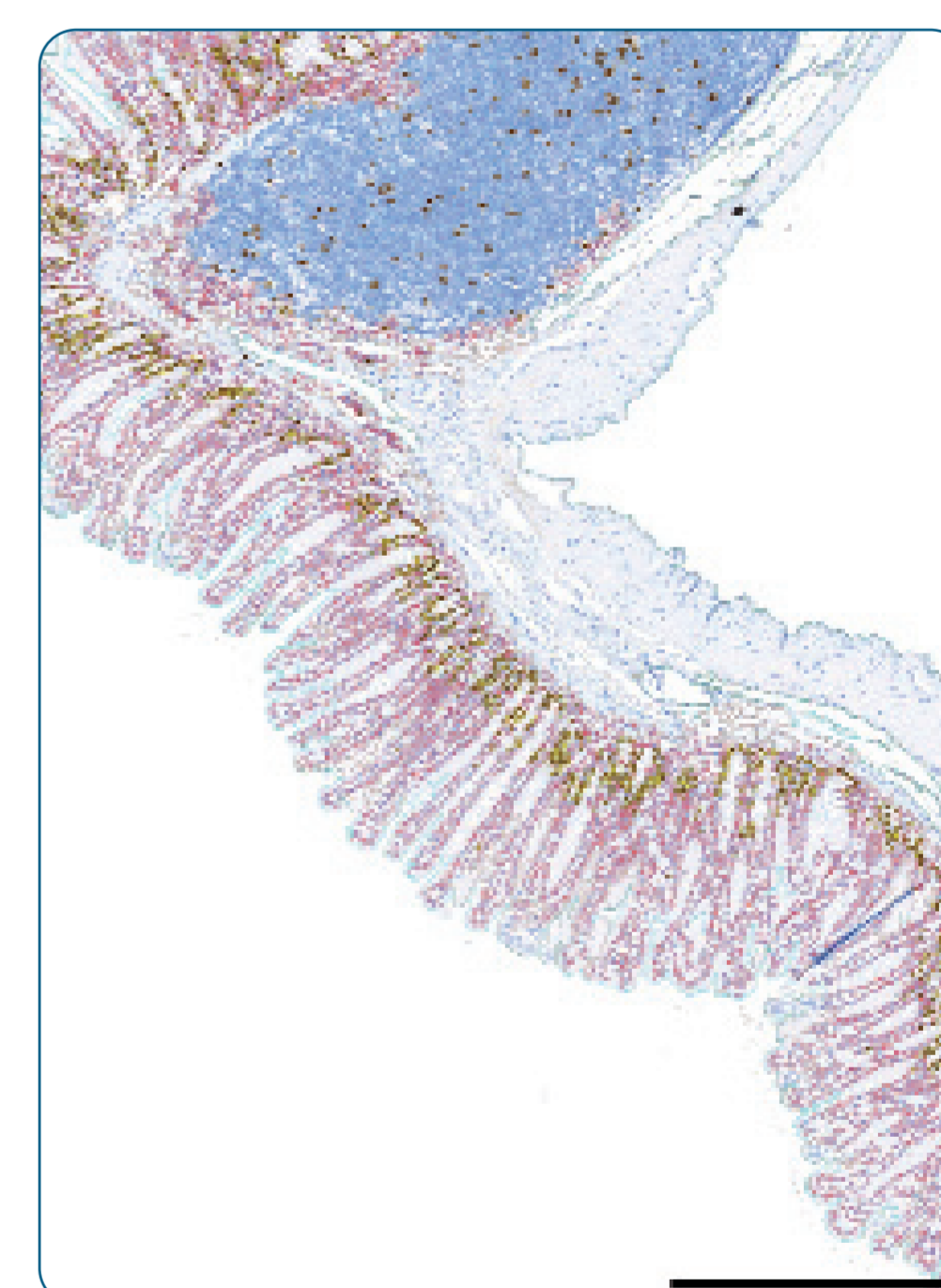
**Table 1** Comparison of Definiens' automated analysis with manual counting. Summary of single image tile data of cecum and colon.



**Fig. 4** Definiens result: Image tiles of cecum from control and treated animal. Note the increased number of positive nuclei and mucosal area. BrdU positive brown nuclei are encircled in yellow, negative nuclei in the mucosa are encircled in red. Bar 200 µm



**Fig. 5** Definiens result: Detection of BrdU positive and negative nuclei in colon mucosa. Positive brown nuclei are encircled in yellow, negative nuclei are encircled in red. Bar 200 µm.



**Fig. 6** Definiens result: Detection of BrdU positive and negative nuclei in cecum. Positive brown nuclei are encircled in yellow, negative nuclei are encircled in red. Lymphatic tissue (dark blue with brown dots) and tissue wrinkle (dark blue line) are excluded from the analysis. Bar 500 µm.

## 5. Discussion

In conclusion, the two rule sets for the cell proliferation evaluation of cecum and colon worked well for the automatic counting on the scanned images. The automatic results are within the range of the results from manual counting by 4 different people on the same randomly selected image tiles. Small inaccuracies in the automatic detection of the mucosal area had no effect on the overall results. With this scanning and image analysis technique a larger area of tissue can be evaluated in a shorter timeframe, resulting in more robust results without painful and time consuming manual work.